

CASE REPORT

Open Access



# Goldenhar syndrome with blepharophimosis and limb deformities: a case report

Xia Ding<sup>1,2</sup>, Xi Wang<sup>1,2</sup>, Yuan Cao<sup>1,2</sup>, Jiaying Zhang<sup>1,2</sup>, Ming Lin<sup>1,2\*</sup>, Xianqun Fan<sup>1,2\*</sup> and Jin Li<sup>1,2\*</sup>

## Abstract

**Background:** Goldenhar syndrome has variable presentations and can affect multiple regions of the body. Diagnoses are based on clinical manifestations. The association of Goldenhar syndrome with blepharophimosis and limb deformities has not previously been reported. Here, we describe a patient who was diagnosed with Goldenhar syndrome in association with blepharophimosis, ocular hypertelorism, hearing loss and limb deformities.

**Case presentation:** A 10-year-old male was first referred to our ophthalmology clinic on 2009–2–11 for ocular hypertelorism and microphthalmia when he had chin-up position. In the first ophthalmic examination, his palpebral fissure length was 19 mm on the right and 20 mm on the left, both palpebral fissure height was 4 mm, the inner intercanthal distance was 63 mm, both upper margin reflex distances were – 1 mm, the myodynamia of the levator palpebrae muscle was 2 mm on the right and 3 mm on the left, and his visual acuity was 20/40 on the right and 20/32 on the left. A physical examination revealed the patient had developed limb deformities in his hands, wrists, elbows and shoulders along with hearing loss. The patient was diagnosed with Goldenhar syndrome because his clinical presentations included ocular hypertelorism, hearing loss, and multiple acral joint deformities. He underwent a first operation in 2009 and a second in 2015. The second operation achieved a satisfactory result in which the horizontal fissure length was 28 mm on both sides, both palpebral fissure height was 10 mm, the inner intercanthal distance was 30 mm, and both of the upper margin reflex distances were 4 mm. He continued to wear hearing aids as usual. His hearing loss and joint deformities were slated for long-term follow-up at his parents' request.

**Conclusion:** The patient, diagnosed with Goldenhar syndrome in association with blepharophimosis, ocular hypertelorism, hearing loss and limb deformities, underwent two operations and achieved a satisfactory result. The patient was submitted to long-term follow-up observations and symptomatic treatments that vary with age and systemic associations, as needed. When treating patients with Goldenhar syndrome, ophthalmology specialists should cooperate with a multi-disciplinary team of clinicians and reach agreement regarding the appropriate systemic and comprehensive treatments.

**Keywords:** Goldenhar syndrome, Blepharoptosis, Limb deformities

\* Correspondence: [linmingcn@163.com](mailto:linmingcn@163.com); [fanxq@sh163.net](mailto:fanxq@sh163.net); [abcd1971206@126.com](mailto:abcd1971206@126.com)

<sup>1</sup>Department of Ophthalmology, Ninth People's Hospital, Shanghai JiaoTong University School of Medicine, No.639 Zhizaoju Road, Shanghai 200025, People's Republic of China

Full list of author information is available at the end of the article



## Background

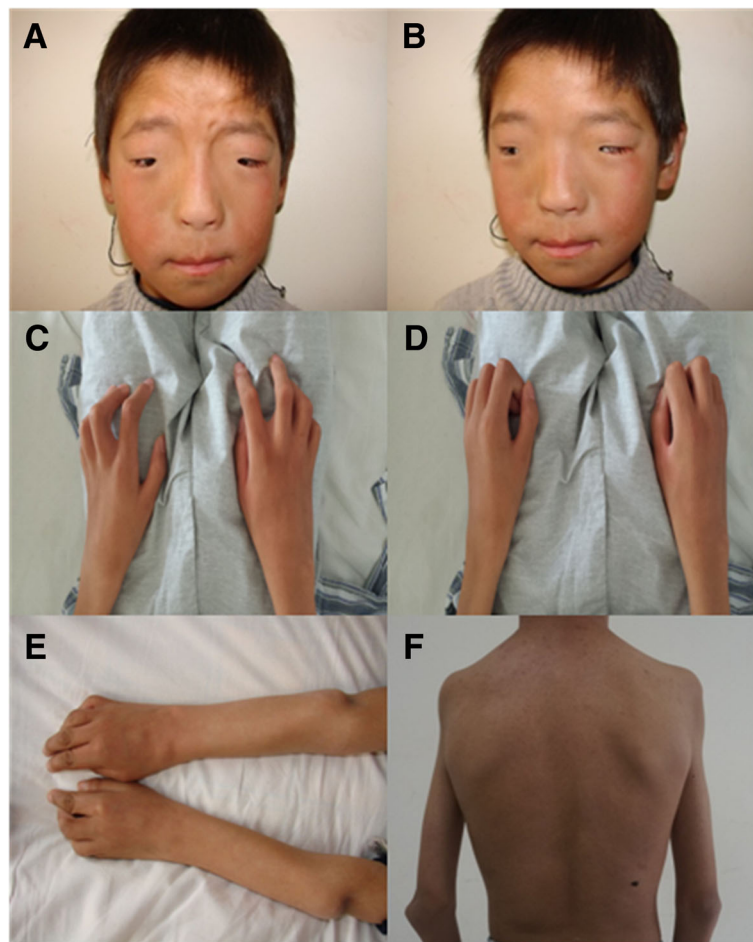
Goldenhar syndrome (GS), also known as oculo-auriculo-vertebral dysplasia, was first described by Von Arlt in 1854 and was named after Dr. Maurice Goldenhar, who reported 3 cases in 1952. In craniofacial malformations that occur during the foetal period, the incidence of GS ranks second only to cheilopalatognathus. The prevalence of GS ranges from 1:4500 to 1:5600 live births and has a male-to-female ratio of 3:2 [1]. There is no agreement in the literature regarding the diagnostic criteria for GS. Currently, a diagnosis depends on clinical manifestations. In particular, GS presents with multiple malformations and various clinical manifestations [2], including ocular abnormalities; aural, facial, and spinal dysplasia and other systemic abnormalities [3].

## Case presentation

A 10-year-old boy was admitted to the Department of Ophthalmology on 2009–2–11 for ocular hypertelorism

and microphthalmia when he had chin-up position. Over the past ten years, neither the inability of the patient to fully open his eyes nor his ocular hypertelorism had improved. He underwent a first operation in our department in 2009 and a second in 2015. The parents were healthy, and their marriage was non-consanguineous. The parents denied a family history of pertinent causes, such as genetic abnormalities or infections.

In the original ophthalmic examination, the palpebral fissure length was 19 mm on the right side and 20 mm on the left side, both palpebral fissure height was 4 mm, the inner intercanthal distance was 63 mm, both upper margin reflex distances were –1 mm, and the myodynamia of the levator palpebrae muscle was 2 mm on the right and 3 mm on the left. The patient had no conjunctival congestion, a transparent cornea, and a normal retina (Fig. 1a and b). The patient's visual acuity was 20/40 in the right eye and 20/32 in the left eye. An orbital CT scan revealed symmetrical line sag in the bilateral anterior



**Fig. 1** An examination performed before surgery showed the following: **a** and **b**: ocular hypertelorism and blepharophimosis. **c** and **d**: the bilateral finger joints were flexed and could not be extended, and the patient could not clench his fists. **e**: elbow malformations. **f**: shoulder malformations

maxillary sinuses, increased density in the bilateral maxillary sinuses, no obvious abnormal orbital structures and no bone destructions (Fig. 2a-d).

The results of a physical examination revealed that the patient had developed bilateral limb deformities in his hands, wrists, elbows and shoulders. The bilateral interphalangeal finger joints were flexed and could not be extended, and the metacarpophalangeal joints and wrists exhibited a limited range of motion. The patient could not clench his fists or fully extend his elbows, which exhibited subluxation (Fig. 1c-1e). He could not fully extend his shoulders, and he exhibited square shoulders and weak adduction (Fig. 1f). He had worn hearing aids (prescribed by a local hospital to treat his sensorineural hearing loss) for 9 years. No intellectual disability was detected during the examination.

The patient wanted to achieve symmetrical and natural-looking cosmetic results. The ophthalmologists performed inner canthus moulding combined with blepharoptosis correction in 2009. The surgical procedure included medial canthoplasty performed using the Mustardé method and frontal muscle flap suspension to correct the ptosis. Post-operatively, the palpebral fissure length was 28 mm on the right and 27 mm on the left, both palpebral fissure height was 8 mm, the inner intercanthal distance was 40 mm, and both of the upper margin reflex distances were 3 mm (Fig. 3a and b).

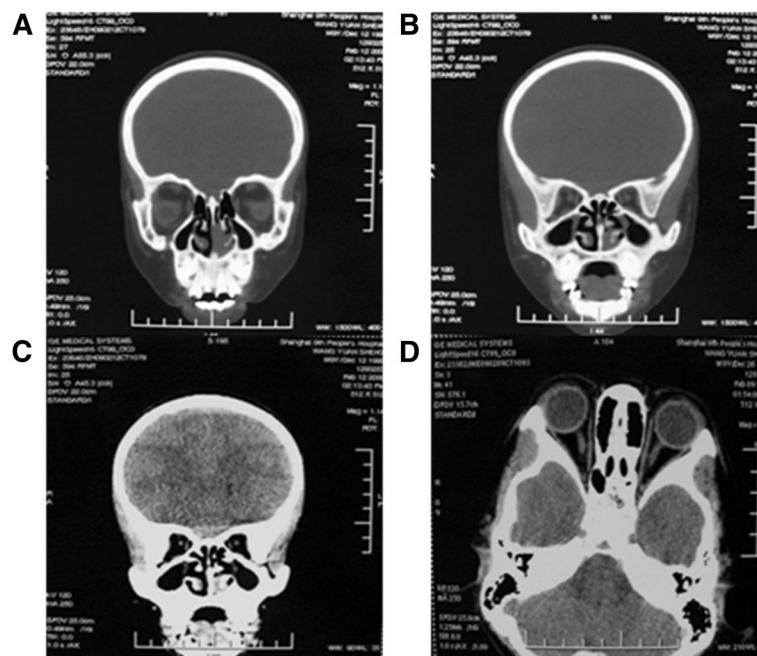
The results of the first operation were not maintained. The palpebral fissure and inner intercanthal distances

regressed. The obtuse deformity of the inner canthus remained. The height of the lateral palpebral fissure remained lower than normal, and both the upper and lower lachrymal points were closed. An ophthalmic examination performed in 2015 revealed the patient's visual acuity was 20/20, the horizontal fissure length was 21 mm on the right and 22 mm on the left, both palpebral fissure height was 6 mm, the inner intercanthal distance was 48 mm and both of the upper margin reflex distances were 2 mm (Fig. 3c and d).

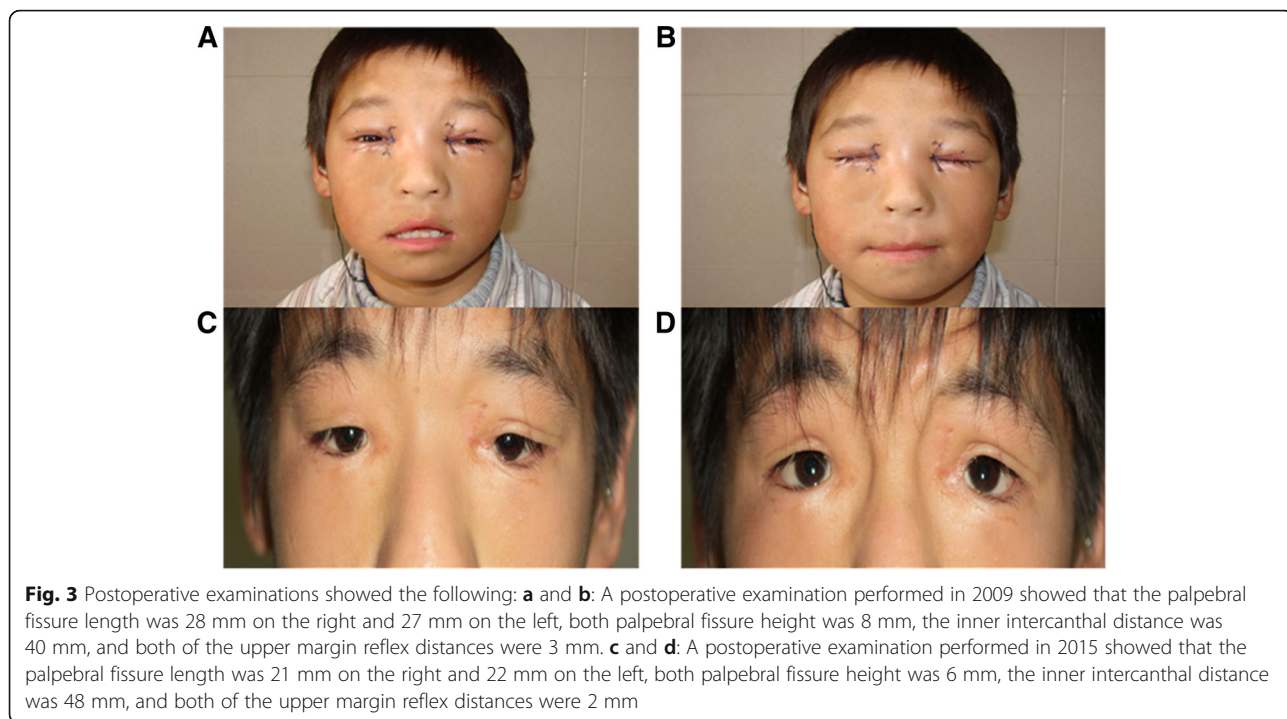
To further improve the patient's appearance, the ophthalmologists performed an inner eye canthus Y-V-plasty with frontal flap suspension in 2015 when the patient was 16 years old. The inner canthus deformity was corrected after the second operation. The horizontal fissure length was 28 mm on the right and 28 mm on the left, both palpebral fissure height was 10 mm, the inner intercanthal distance was 30 mm, and both of the upper margin reflex distances were 4 mm (Fig. 4a and b). These results were stable after more than 1 year.

## Discussion

GS is associated with a genetic predisposition and is characterized by epibulbar, aural, facial, and spinal dysplasia in addition to, in some cases, cardiac, renal, and central nervous system anomalies [4]. A diagnosis of GS includes the following clinical manifestations: auricular agenesis, hemifacial microsomia, oblique facial cleft, epibulbar dermoids and/or upper eyelid colobomas, and



**Fig. 2 a-d** An orbital CT performed in 2009 showed the following: symmetrical line sag in the bilateral anterior maxillary sinuses with normal bone structures in the orbit



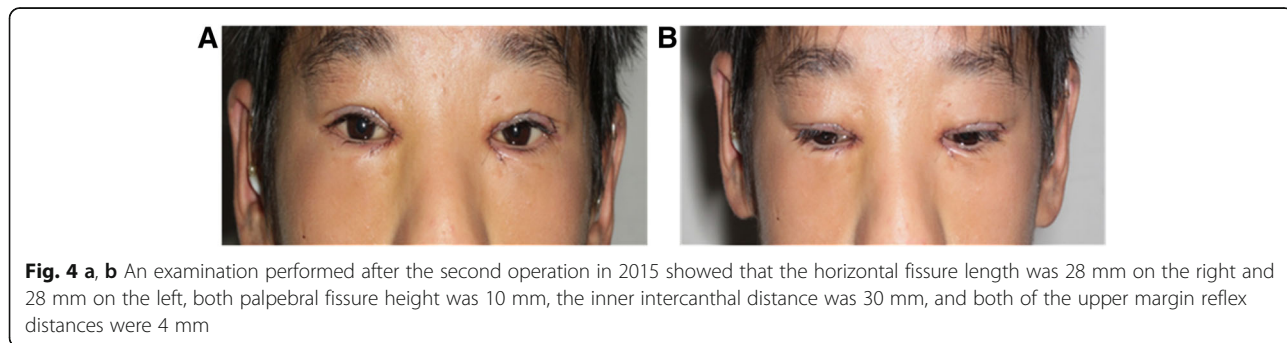
vertebral anomalies [5, 6]. In addition to these typical malformations, Bowen et al. [7] suggested that affected patients might also have variable abnormalities, such as unilateral or bilateral facial macrosomia, cleft palate, high palatal arch, bifid tongue, bregmatic patency, orbital hypertelorism, small hypophyseal fossa, low hairline, equinus, dumbness, Tetralogy of Fallot, bundle-branch block, lateral ventral syndrome, mild apnoea, epilepsy, hydronephrosis, hydroureterosis, anal atresia, or recto-vaginal fistula.

Some patients with GS have clinical findings that overlap with those of other syndromes, such as Treacher Collins syndrome [8], Townes–Brocks syndrome [9], CHARGE syndrome [10], Branchio-oto-renal spectrum disorders [11], and the phenotypic spectrum associated with mutations in EFTUD2 [12, 13]. In the case described here, the patient’s clinical presentations included ocular hypertelorism, hearing loss, and multiple acral

joint deformities. Our case was consistent with many previously described cases, including patients 26 and 28 in a study of approximately 51 Oculo-auriculo-vertebral spectrum(OAVS)patients [14]. The clinical manifestations observed in our patient were closely related to GS, of which blepharophimosis with limb deformities is a characteristic manifestation.

We believe that these manifestations are distinctive and recognizable phenotypic entities. However, if a patient’s features are sufficiently suggestive, molecular testing for genes related to these syndromes might be considered in some patients with GS.

In view of his parents’ strong desire for surgical management of his ocular deformities and to have a direct and positive influence aimed at producing psychosocial and social benefits, it was decided that the patient would undergo surgery to improve his facial appearance. The main aim was to correct the inner canthus deformity.





The first operation significantly improved the blepharophimosis and shortened the inner intercanthal distance. However, an obtuse deformity of the inner canthus remained. The second operation achieved ideal results. In these types of abnormalities, it is better to correct an inner canthus deformity in the first surgery and to subsequently perform a ptosis surgery. The upper and lower lachrymal point closure accompanied by a lack of tear production that was exhibited by this patient may have been caused by low lachrymal gland secretion, which can represent a compensatory mechanism caused by the deformity. A Schirmer I test revealed a Schirmer of 5 mm, But with 8 s and did not indicate excessive tear production. Because no obvious dry eye syndrome was observed, lachrymal recanalization was not performed. There was no need to treat the patient's long-term hearing loss or joint deformities after consultation with ear-nose-throat and orthopaedic clinics as neither condition had a significant impact on his quality of life. We recommended that the patient wear hearing aids as usual and that he submit to long-term follow-up observations and symptomatic treatments as needed.

## Conclusion

In this disease, timely detection and intervention can lead to satisfactory surgical outcomes. To obtain a comprehensive assessment, ophthalmology specialists should consult with ear-nose-throat, orthopaedic, neurosurgery, and paediatric clinics, and these entities should plan the best possible interventions that will achieve optimal results for patients with GS. Systemically evaluating patients with GS is important to their diagnosis and enables early intervention to treat the abnormalities that can potentially occur in these patients.

## Abbreviations

GS: Goldenhar syndrome; OAVS: Oculo-auriculo-vertebral spectrum

## Acknowledgments

We are most grateful to Professor Shengfang Ge who helps to revise the manuscript as well as to the clinicians and researchers who made this work possible.

## Ethical approval and consent to participate

The study was carried out according to the principles of the Declaration of Helsinki and Shanghai Ninth People's Hospital Ethics Committee approved the study. The patient images that are contained in this article were captured by a hospital-based photographer at Shanghai Ninth People's Hospital, Shanghai Jiao Tong University School of Medicine.

## Funding

This work was supported by the Science and Technology Commission of Shanghai (16ZR1419600,17DZ2260100).

## Availability of data and materials

The datasets during and/or analyzed during the current study are available from the corresponding author on reasonable request.

## Authors' contributions

In this report, XD and YC drafted and revised the article; ML, XF and JL were involved in managing and treating the patients; and XW and JZ reviewed the patient's records. All authors read and approved the final manuscript.

## Consent for publication

Written informed consent was obtained from the patient's parents for publication of this case report and any accompanying images. A copy of the written consent is available for review by the Editor of this journal.

## Competing interests

All authors approved this manuscript and declared that they have no competing interests.

## Publisher's Note

Springer Nature remains neutral with regard to jurisdictional claims in published maps and institutional affiliations.

## Author details

<sup>1</sup>Department of Ophthalmology, Ninth People's Hospital, Shanghai JiaoTong University School of Medicine, No.639 ZhizaojuRoad, Shanghai 200025, People's Republic of China. <sup>2</sup>Shanghai Key Laboratory of Orbital Diseases and Ocular Oncology, Shanghai, China.

Received: 4 March 2018 Accepted: 26 July 2018

Published online: 22 August 2018

## References

- Brue C, Mariotti C, Celani S, Rossiello I, Giovannini A. A case of Goldenhar syndrome associated with a new retinal presentation: exudative vitelliform maculopathy. *Case Rep Ophthalmol Med.* 2015;2015:626027.
- Martelli H Jr, Miranda RT, Fernandes CM, Bonan PR, Paranaiba LM, Graner E, et al. Goldenhar syndrome: clinical features with orofacial emphasis. *J Appl Oral Sci.* 2010;18:646–9.
- Linder M, Fittschen M, Seidmann L, Bahlmann F. Intrauterine death of a child with Goldenhar syndrome: a case presentation and review of the literature. *Arch Gynecol Obstet.* 2012;286:809–10.
- Anderson PJ, David DJ. Spinal anomalies in Goldenhar syndrome. *Cleft Palate Craniofac J.* 2005;42:477–80.
- Jakobiec FA, Pineda R, Rivera R, Hsu-Winges C, Cherwek D. Ep corneal polypoidal lipodermoid: lack of association of central corneal lesions with goldenhar syndrome verified with a review of the literature. *Surv Ophthalmol.* 2010;55:78–84.
- Ottaviano G, Calzolari F, Martini A. Goldenhar syndrome in association with agenesis of the internal carotid artery. *Int J Pediatr Otorhinolaryngol.* 2007; 71:509–12.
- Bowen DL, Collum LM, Rees DO. Clinical aspects of oculo-auriculo-vertebral dysplasia. *Br J Ophthalmol.* 1971;55:145–54.
- Katsanis SH, Jabs EW. Treacher Collins syndrome. In: Pagon RA, Adam MP, Ardinger HH, Wallace SE, Amemiya A, Bean LJH, et al., editors. *GeneReviews*. Seattle WA: University of Washington; 1993.
- Kohlhase J. Townes-brocks syndrome. In: Pagon RA, Adam MP, Ardinger HH, Wallace SE, Amemiya A, Bean LJH, et al., editors. *GeneReviews*. Seattle, WA: University of Washington; 1993.
- Lalani SR, Hefner MA, Belmont JW, Davenport SLH. CHARGE syndrome. In: Pagon RA, Adam MP, Ardinger HH, Wallace SE, Amemiya A, Bean LJH, et al., editors. *GeneReviews*. Seattle, WA: University of Washington; 1993.
- Smith RJH. Branchiootorenal spectrum disorders. In: Pagon RA, Adam MP, Ardinger HH, Wallace SE, Amemiya A, Bean LJH, et al., editors. *GeneReviews*. Seattle, WA: University of Washington; 1993.
- Gordon CT, Petit F, Oufadem M, Decaestecker C, Jourdain AS, Andrieux J, et al. EFTUD2 haploinsufficiency leads to syndromic oesophageal atresia. *J Med Genet.* 2012;49:737–46.
- Voigt C, Megarbane A, Neveling K, Czeschik JC, Albrecht B, Callewaert B, et al. Oto-facial syndrome and esophageal atresia, intellectual disability and zygomatic anomalies-expanding the phenotypes associated with EFTUD2 mutations. *Orphanet J Rare Dis.* 2013;8:110.
- Beleza-Meireles A, Hart R, Clayton-Smith J, Oliveira R, Reis CF, Venancio M, et al. Oculo-auriculo-vertebral spectrum: clinical and molecular analysis of 51 patients. *Eur J Med Genet.* 2015;58:455–65.